



MANAGEMENT OF RETROPERITONEAL SARCOMAS IN PUBLIC SECTOR HOSPITAL OUR EXPERIENCE

DR SULEMAN ASIF, PROF DR JAVAID UR REHMAN, DR AWAIS AMJAD MALIK, DR JEHANZAIB RASHID, DR MUHAMMAD AHSAN ALAM, DR SADIHA SAEED I SERVICES HOSPITAL LAHORE

BACKGROUND

Retroperitoneal sarcomas are rare malignant tumors. Data from public sector hospitals, however, remain limited.

METHODOLOGY

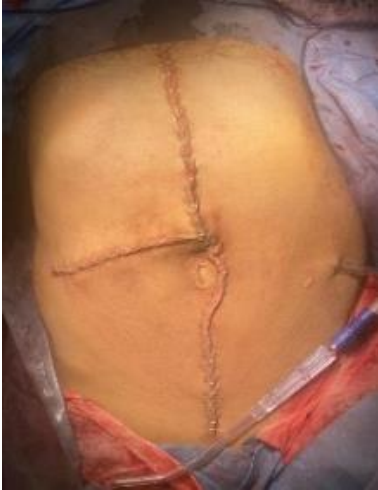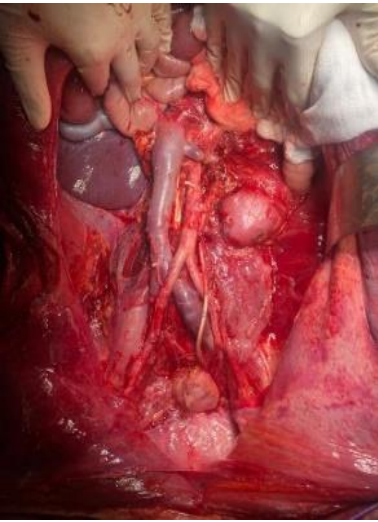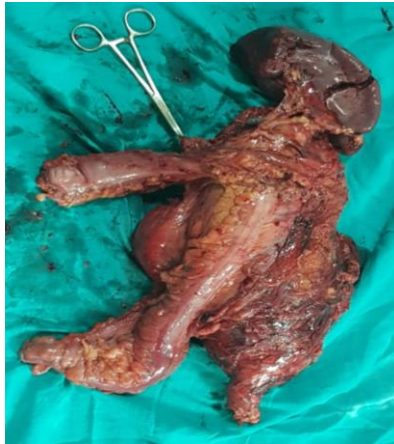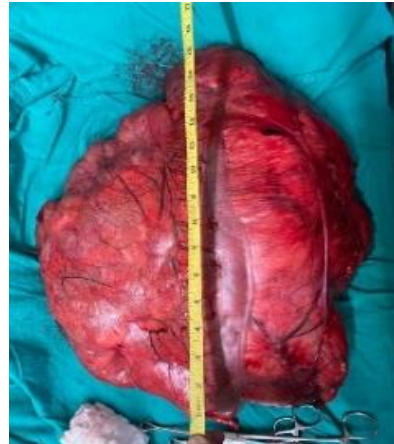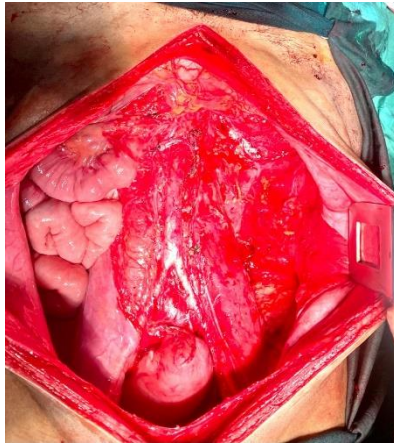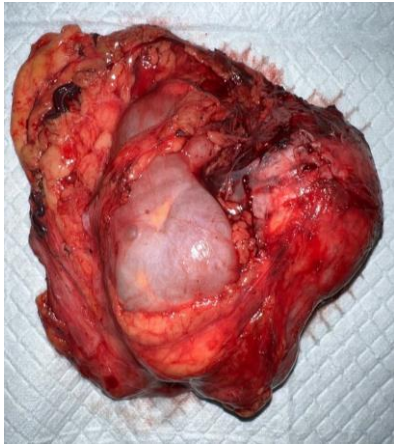
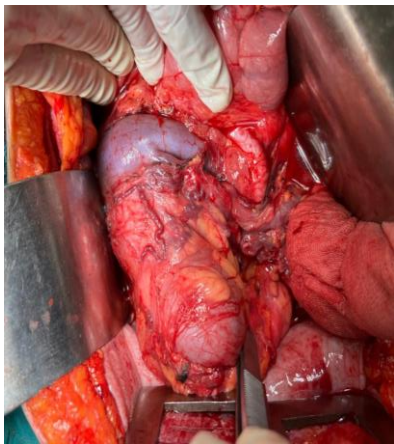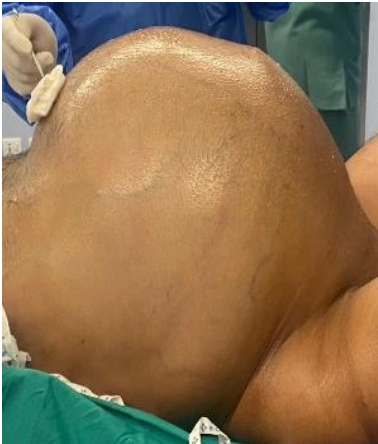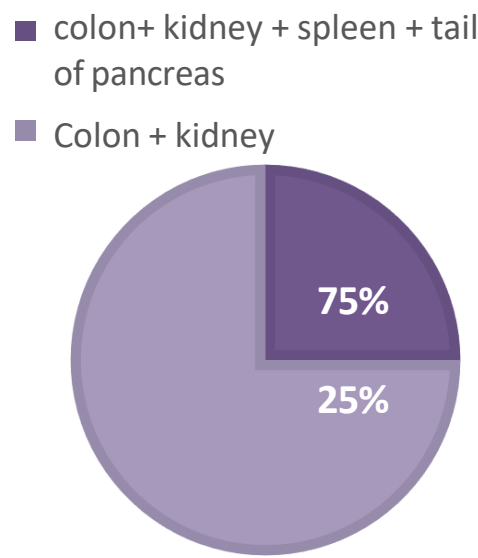
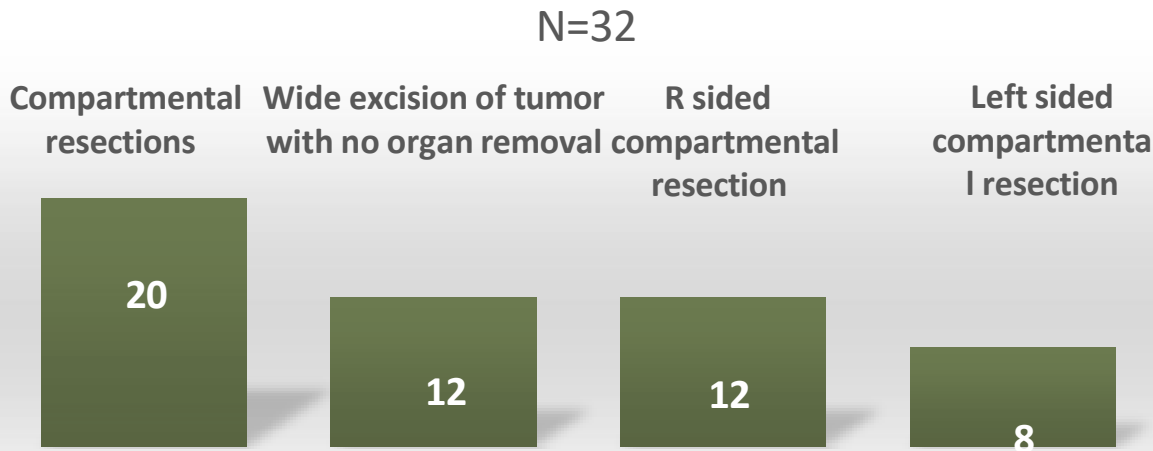
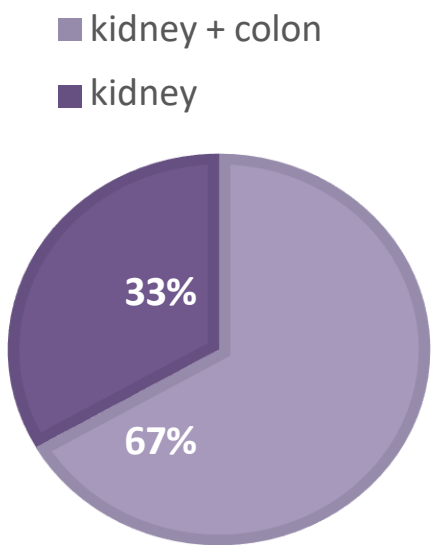
Observational study Jan2017 - August 2025
Total no of patients 32.
.Surgical procedures and perioperative outcomes

R compartmental resection	N=12
Kidney + colon	8
Kidney only	4

RESULTS

- Total patients= 32
- Recurrent =6 , upfront =26
- Compartmental resection 20
- Wide local excision with no organ removal=12
- Mortality due to anastomotic leak and sepsis- 1

L compartmental resection	N=8
colon + kidney	2
Colon+ kidney + spleen + tail of pancreas	6



COMPLICATIONS

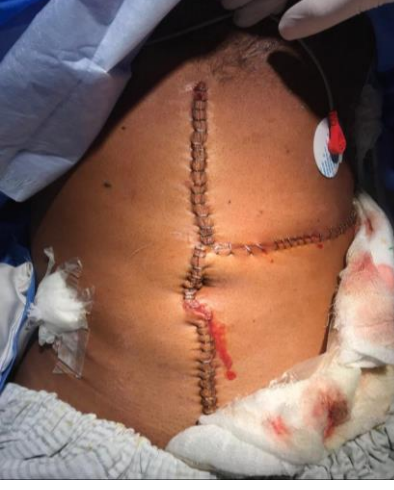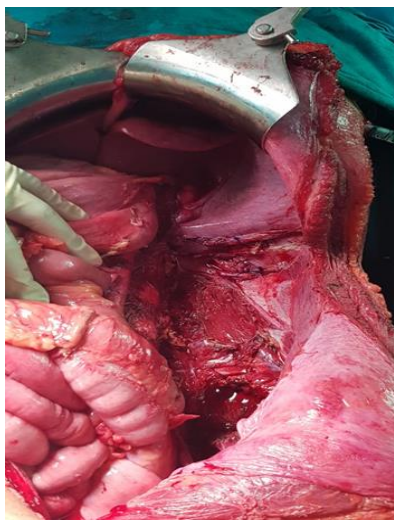
1. Complications were seen in 6 patients
2. 3 patients developed post op wound infections
3. One patient had a prolonged hospital stay due to ileus
4. One mortality. Patient was shifted to ICU due to post op complications including sepsis and died on post op day 10th.

ONCOLOGICAL OUTCOMES

- R0 resection was done in 27 patients
 - R1 resection in 4 patients
- 28 patients are on close follow-up with no recurrence

HISTOPATHOLOGY

Differentiated	8
Dedifferentiated	16
Undifferentiated	3



References:

- Garcia-Ortega DY, Martinez-Said H, Luna-Ortiz K, Herrera-Gomez A, Serrano-Olvera A, Angeles-Angeles A, et al. Comprehensive treatment strategy for improving surgical resection rate of retroperitoneal sarcomas: a histology-specific approach. *Front Oncol.* 2024;14:1432900. Available from:
- Bonvalot S, Gronchi A, Strauss DC, et al. Multivisceral resection for retroperitoneal sarcoma: outcomes from a European multicenter cohort. *Eur J Surg Oncol.* 2023;49(5):1012–1019.
- Zhang Y, Chen L, Wang J, et al. Global trends in retroperitoneal sarcoma surgery: a bibliometric analysis. *J Cancer Surg Res.* 2025;17(2):e03630.